

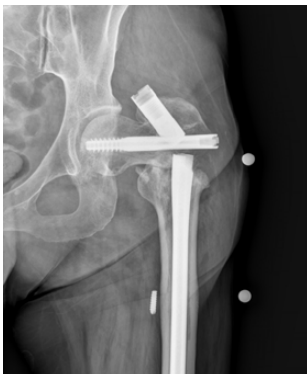# Orthopedic Surgery Update

Current Trends from the Department of Orthopedic Surgery Vol. 16, No. 2, 2022

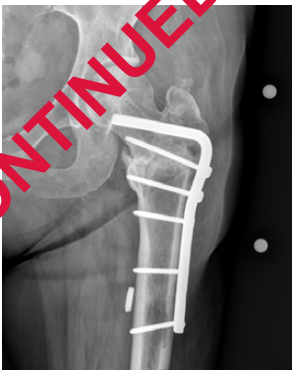JULY 2022

## In this issue

- 2 Knee Cartilage Graft Procedure Restores Malunited Wrist Joint
- 4 Osseointegration: Making Prosthetics Possible for High-Leg Amputations
- 5 Obesity and Total Joint Arthroplasty
- 6 RPNI Lowers Post-Amputation Pain



**Figure 1.** Proximal femur nonunion with hardware failure.



**Figure 2.** Repair of left proximal femur nonunion with hardware failure.

## A Comprehensive, Expedited Approach for Nonunions

Krystin A. Hidden, M.D., an orthopedic surgeon at Mayo Clinic's campus in Rochester, Minnesota, is passionate about nonunion repair, which is when a surgically repaired fracture from trauma never heals. Patients often come to see her or her colleagues because they are symptomatic despite surgical fracture repair months previously, experiencing persistent pain where the extremity is typically stable. In other cases, patients experience hardware failure: if the bone has not healed, the hardware may begin to break.

"It's a race between the bone healing and the implant failing. If I see hardware shifting, I have a high suspicion for nonunion," says Dr. Hidden.

While studying a patient's case, she asks these questions:

- **Biomechanics.** Were appropriate implants and hardware used in the previous surgery?
- **Biology.** Is the necessary biology present to achieve complete healing? Is there a large incision with significant tissue stripping?
- **Infection.** Are any infection signs present?
- **Stability.** Is the bone stable with the current hardware?
- **Bone loss.** Is there bone loss? Is a bone graft needed from a different body part or from a deceased donor? Would the bone need a 3D-printed allograft?
- **Nutrition and hormones.** Is the patient deficient in calcium or vitamin D? Are any hormones working improperly?

- **Polytrauma.** Did the patient experience additional injuries, multiplying the total healing time needed?
- **Nature of injury.** Where and how did the fracture occur? Was it a high-energy injury? Did it result in an atypical femur fracture? An open injury with protruding bone?

### DETERMINING RISK FACTORS PRIOR TO NONUNION SURGERY

Beyond considering these aspects of the case, Dr. Hidden ascertains any risk factors that may impact nonunion repair outcome, such as:

- Diabetes
- Tobacco smoking status
- Immune-modulating agents or medications
- Morbid obesity
- Peripheral neuropathy

Dr. Hidden and colleagues collaborate with patients with these risk factors to help them achieve the biology necessary for successful nonunion repair. For patients with diabetes, she partners with Mayo Clinic endocrinologists, who help patients control their glycated hemoglobin (hemoglobin A1C), targeting a range of 5.6 to 6 or lower. Dr. Hidden refers patients who smoke tobacco to a smoking cessation program. Successful nonunion repair requires tobacco-free status, as any nicotine in the system impacts blood vessel diameter and decreases healing.



Krystin A. Hidden, M.D.

Dr. Hidden states, “It’s hard to fill a swimming pool with a water hose. Nicotine decreases blood vessel diameter, which in turn can’t deliver the nutrients required for successful healing.”

Immune-modulating agents can produce inadequate healing responses, especially in the setting of chronic steroids, antirheumatic medications, radiation or chemotherapy. She discusses elevated nonunion surgical risk with patients with morbid obesity, including increased infection risk and wound-healing issues. She refers these patients, if they elect to proceed, to Mayo Clinic weight-loss experts for guidance in lowering body mass index (BMI) prior to surgery.

An orthopedic surgeon also must rule out infection before nonunion repair. If present, at least two procedures are usually necessary to clear the infection. “If the skin or limb is at risk, it swings the pendulum toward more-emergent surgery,” says Dr. Hidden.

She feels working with patients pre-surgically on modifiable risk factors is a key part of her role in their treatment. Tobacco is one such modifiable risk factor. She recognizes that smoking cessation is a challenge.

Ultimately, however, she collaborates with the patients needing nonunion surgery to weigh the risks and benefits to determine if the surgery will be safe and effective.

“I would not recommend nonunion surgery if it would harm the patient or not improve the quality of life,” says Dr. Hidden.

In some cases, nonunions may be treated without surgery. She indicates that correcting deficient levels of vitamin D and calcium could prevent the need for nonunion surgery at all. If these nutrients are insufficient — not just low

vitamin D in particular is common in the Northern Hemisphere — she refers the patient to Endocrinology for supplement intervention and even bone-building medications in select cases. She says nonunion specialists work as a team with Endocrinology, and she collaborates with colleagues in this discipline, often during the same preoperative visit.

#### NONUNION REPAIR METHODOLOGY

Nonunion treatment (Figures 1 and 2, see page 1) depends on whether the patient is symptomatic, says Dr. Hidden. Most nonunion repairs involve biological adjuncts, preferably using the patient’s own biology, either from the same bone presenting with nonunion or from the iliac crest or pelvis bone. If necessary for sufficient bone volume, the orthopedic surgeon may expand the biologics from the patient’s body with donor bone or by taking bone from another area in the body. Though most patients accept donor bone use, if needed, Dr. Hidden indicates that cultural or religious factors occasionally cause patients to prefer different options.

Another alternative is to use bone graft substitutes to repair the nonunion, such as calcium phosphate bone cement.

While nonunions occur most frequently with lower extremities, a similar problem may arise in a repaired upper extremity, with gross mobility requiring further surgery.

#### WHEN TO REFER OR TREAT LOCALLY FOR NONUNIONS

For orthopedic surgeons familiar and comfortable with nonunion repair, Dr. Hidden indicates it makes sense for them to operate on patients with this condition in the community. However, for surgeons trained in other aspects of orthopedics who are not as familiar with nonunions, she suggests a referral to Mayo Clinic’s Orthopedic Trauma Service specialists.

## Knee Cartilage Graft Procedure Restores Malunited Wrist Joint

When Keith T. Aziz, M.D., an orthopedic surgeon specializing in hand and upper extremity surgery at Mayo Clinic’s campus in Florida, first saw the young basketball player, he noted the boy was not experiencing pain, yet had significant issues with range of motion (ROM).

“He had a pothole in his wrist joint,” he says. “His wrist fracture healed in a bad position — and the carpal bones were stuck in the hole.”

The reason for the hole present in the boy’s wrist joint was an impaction fracture. It was not initially recognized and progressed to a malunion. Distinct from a nonunion, where

there is no healing in the joint, a malunion indicates nonanatomical healing, which can be a complication from surgery or something that occurs when non-surgical management doesn't maintain the appropriate position of the bones.

In the young basketball player's case, no surgery had been performed on his wrist initially, as his health care providers at the time did not recognize the extent of injury. He had a different injury pattern from what is commonly seen in the wrist. In this case, only one part of the joint surface was affected — appearing almost like a die punch in that location — where typical wrist injuries either impact a larger portion of the joint or are outside of the joint altogether. This was a fracture in the scaphoid fossa, part of the joint that supports the scaphoid bone. Though small, this injury and its subsequent malunion caused swelling and limited use of the wrist. In some patients, a wrist malunion can cause the wrist joint to become completely unusable.

#### TRADITIONAL VERSUS CARTILAGE GRAFT WRIST FRACTURE REPAIR

A traditional wrist fracture repair would include an osteotomy. However, this procedure, with its usual bone cutting and removal, would be difficult to perform in a contained defect in a small area of the joint surface, says Dr. Aziz.

Due to the nature of the malunion in the basketball player's case, Dr. Aziz elected to take a knee cartilage graft in a non-weight-bearing region to repair the wrist joint. Though this was a unique repair for the player's injury, his parents agreed to pursue it. As the young patient was still skeletally immature with his growth plates open, Dr. Aziz projected and accounted for his future growth in the repair. He also removed the physeal bar that developed from his wrist trauma, as the bar attaches to part of the joint, disallowing growth in line with the bar.

A knee cartilage graft repair should last the rest of a patient's life once the joint heals correctly, says Dr. Aziz.

Dr. Aziz indicates this repair may have minimal scarring and only slightly less or equivalent ROM than that of the uninjured wrist. Today, the basketball player, who had the surgery during training season, continues to do well, has no limitations and has resumed basketball activity. His ROM is now as good and functional as the side with no joint injury.

This surgery's distinction was that it represented the first time a knee cartilage graft technique for wrist malunion was used in a pediatric patient and also for this particular injury.

#### APPLICATIONS OF THE KNEE CARTILAGE GRAFT FOR WRIST MALUNION REPAIR

Surgeons can perform the same type of knee cartilage graft for wrist malunion for adults as the basketball player experienced. The procedure is easier to perform in this population — considering future growth is not necessary, as it is in pediatric patients. Wrist joint injury can occur through a number of mechanisms — whether a slip in the kitchen, loss of balance on a neighborhood walk, or a fall while skiing or performing another physical activity. Older adult patients, in particular, experience wrist fractures often and tend to have more significant injuries.

Recovery from the knee cartilage graft procedure to repair the wrist includes casting for a defined period and then a removable orthosis, typically with a 6- to 8-week healing time after which the surgeon will approve use of the joint.

#### SUGGESTIONS FOR PHYSICIANS PERFORMING THE PROCEDURE OR WHO ELECT TO REFER

Procedures such as cartilage grafting to repair wrist malunion typically are performed by subspecialists — hand and upper extremity orthopedic surgeons — says Dr. Aziz. He suggests the following steps are needed prior to malunion surgery:

- Advanced imaging to characterize the malunion
- Understanding the origin of the wrist malunion
- Confirmation of appropriate diagnosis

After these steps are completed, Dr. Aziz suggests developing a surgical plan or referring to a facility such as Mayo Clinic for the surgery. At the time of initial wrist injury, surgery within two weeks is crucial before the bone begins healing and becomes difficult to position. However, after malunion has occurred in the joint, the time frame in which an orthopedic surgeon must perform the procedure depends on the injury pattern.

"Though no longer considered a medical emergency, the sooner it's repaired, the better — as this protects the articular cartilage," says Dr. Aziz.



Keith T. Aziz, M.D.



# Osseointegration: Making Prosthetics Possible for High-Leg Amputations



Benjamin K. Wilke, M.D.

Orthopedic surgeons at Mayo Clinic in Florida are now performing osseointegration, a technique to attach a prosthesis directly to bone, making it easier to use for patients with short residual limbs following an amputation. They are using the first Food and Drug Administration (FDA)-approved osseointegration implant in the United States. This procedure has been performed previously at a military facility, Walter Reed Army Medical Center, and is now available for the civilian population.

“In certain cases, the residual limb is too short for a traditional socket-style prosthesis,” says Benjamin K. Wilke, M.D., an orthopedic surgeon at Mayo Clinic in Florida. “These are usually very high amputations. Typical prosthetics need enough surface area for the socket to hold. They can get good suction and seal with below-knee amputations. However, if amputations are close to the hip, it becomes more challenging.”

## BRIEF OSSEOINTEGRATION HISTORY AT MAYO CLINIC AND WORLDWIDE

In May 2021, orthopedists at Mayo Clinic in Florida performed the first osseointegration for a patient who lost a leg to cancer. The patient now ambulates with one crutch and is working with a physical therapist to remove all gait aids. A second patient recently completed stage 2 of the two-stage procedure, and a third patient completed stage 1. Dr. Wilke says patients with high above-knee amputations appropriate for osseointegration often have required limb removal following cancerous tumors or other diseases, or irreparable or life-threatening damage from traumatic incidents such as motor vehicle crashes. Osseointegration arose from efforts in Europe to find solutions for patients who failed traditional sockets used for prosthetic devices. Surgeons in Europe, says Dr. Wilke, have more experience with the procedure than do surgeons in the United States. Osseointegration arrived stateside mostly for blast injury use at Walter Reed. Dr. Wilke says osseointegration now is spreading to U.S. academic medical centers, predicting it will become commonplace in 5 to 10 years.

Mayo Clinic orthopedic surgeons formed a unique relationship with a physiatrist at Brooks Rehabilitation Hospital to whom

they'd refer patients post-amputation. Dr. Wilke, Mayo colleagues and the Brooks physiatrist considered potential techniques to improve fastening and prosthesis use for patients with high-leg amputations. This collaboration continues today with osseointegration at Mayo Clinic in Florida then referral to Brooks for rehabilitation.

## HOW OSSEOINTEGRATION WORKS

Osseointegration (Figure) is a unique method to connect prosthetics and residual limbs, removing the socket. The surgery begins with screw implantation. After 6 weeks to 3 months of healing, the orthopedist performs the second surgery, inserting the abutment to which the prosthetic limb will attach. Plastic surgery teams assist during this procedure with flap development.

There is a risk of infection with osseointegration. Infections are usually mild and require oral antibiotics for 1 to 2 weeks. Osseointegration includes built-in safety features. If patients fall post-procedure, they can hypothetically fracture the remaining bone. But the technology includes a torque limiter that is designed to limit the force on the bone. If patients fall down the stairs, hitting with significant force, the prosthetic is designed to break away, similar to skis when skiers crash.

Dr. Wilke considers Mayo Clinic in Florida's osseointegration practice distinct in its coordinated team effort, with strong relationships between Mayo orthopedic and plastic surgeons and with the rehabilitation hospital physiatrist, along with a significant support structure.

Though osseointegration is possible for many with near-hip amputations, contraindications include severe diabetes, vascular issues and infection, the last of which historically has been challenging with amputations. Osseointegration also is inappropriate for long residual limbs post-amputation, as it would require bone removal to avoid knee imbalance.

## DR. WILKE'S EARLY OBSERVATIONS ON OSSEOINTEGRATION

Dr. Wilke is excited about what osseointegration provides for eligible patients.

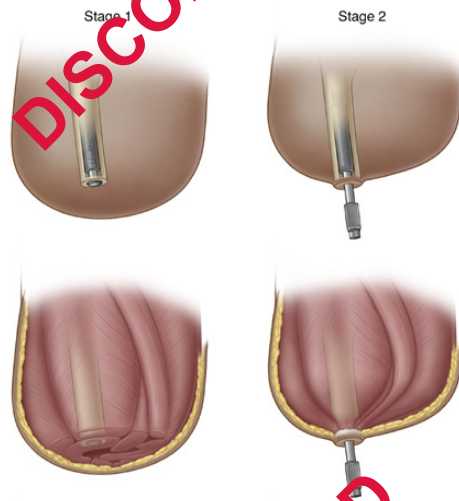

Figure. The process of osseointegration in stages for patients with short residual limbs post-amputation.

"The patients have significantly better mobilization," he says. "One patient is able to do walks up and down ramps almost like someone without a prosthetic. The gait is much closer to someone's gait unaffected by amputation — better than with suction-based prosthetics. The energy expended to walk is also less."

With osseointegration, patients also have significant prosthetic sensory abilities Dr. Wilke finds intriguing.

"Sensory receptors in the bone allow patients to close their eyes standing on tile, move their legs and tell when the prosthetic foot slides between two tiles," he says.

Though initial osseointegration costs more than a socket, Dr. Wilke anticipates the procedure's cost over time will be lower. The cost savings will be realized from fewer needed prosthetic modifications.

## MAYO CLINIC IN FLORIDA OSSEOINTEGRATION PRACTICE AND PATIENT REFERRALS

Because osseointegration is not offered everywhere, yet useful for patients with high above-knee amputations, Dr. Wilke anticipates self-referrals. He also welcomes referrals from physicians whose patients would benefit from the procedure.

He suggests allowing patients with high above-knee amputations to heal, then sending them to Mayo Clinic in Florida for osseointegration quickly, rather than referring them years later.

"This is new and exciting for the world of people with amputations," says Dr. Wilke. "We want to help these patients experience as high a quality of life as possible with prosthetics that allow them to participate in activities meaningful to them."

## Obesity and Total Joint Arthroplasty

The proposition of total knee arthroplasty (TKA) or total hip arthroplasty (THA) for a patient with morbid obesity — an individual with a BMI of 40 or greater — requires careful risk and benefit assessment by the orthopedic surgeon and the patient, according to Nicholas A. Bedard, M.D., an orthopedic surgeon at Mayo Clinic's campus in Rochester, Minnesota.

As BMI goes up, so does risk of complications," he says. "The risks start to increase exponentially at a BMI of 40."

He says even for patients with a BMI of 30, risk level increases slightly compared with that of patients who have a BMI under 30.

### POTENTIAL RISKS AND CHALLENGES FOR PATIENTS WITH 40-PLUS BMI

BMI is independently associated with increased risk of postoperative complications after THA and TKA (figures 1 and 2, see pages 5 and 6) says Dr. Bedard. He also indicates obesity usually does not occur in a vacuum, without other health consequences. In fact, it can be a marker of poor overall wellness: Individuals who have a 40-plus BMI tend to be overall less healthy, and often have other medical problems that can increase their risk of complications.

Potential risks and challenges for performing a TKA or THA for a patient with morbid obesity include:

- Soft tissue depth, which makes implant

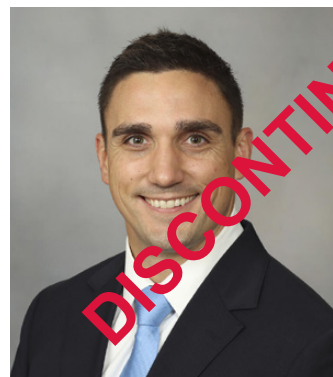- positioning more difficult for the surgeon
- Increased risk of wound complications
- Elevated infection risk
- Increased risk of THA dislocation due to soft tissue impingement or tissue levering the joint out of place

Dr. Bedard says infection after TKA and THA is a significant risk for patients with 40-plus BMI, often leading to one or two additional surgeries and worse function.

Yet, despite greatly increased TKA or THA risks and challenges for those with morbid obesity, these patients are still debilitated by arthritis, and the need persists to help them.

"It's hard to deny someone a procedure just based on BMI cutoff," says Dr. Bedard, considering the example of a patient who has a BMI of 52 and who smokes cigarettes and has diabetes, and how additional comorbidities like these compound each other. "We work with them individually to manage their risk factors to improve the likelihood of getting them through surgery safely."

According to Dr. Bedard, patients with morbid obesity who do not experience any complications post-TKA or post-THA do as well as patients with lower BMI after surgery, experiencing good outcomes, including decreased pain and improved function. "Patients with morbid obesity can have



Nicholas A. Bedard, M.D.

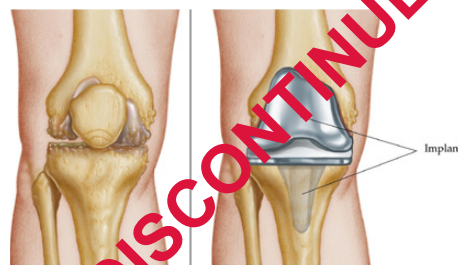

Figure 1. Arthritic knee and repair with total knee arthroplasty.

DISCONTINUED

similar functional increases after TKA or THA as patients with lower BMI who have the surgery,” says Dr. Bedard. “The vast majority get through surgery successfully. The main difference is comparative risk, which can be 2 to 5 times higher than that of patients who have lower BMI.”

He acknowledges, however, that regardless of BMI, no surgery is risk-free.

“Every surgery has risk,” he says. “You have to work with the patient to say, ‘What’s an acceptable risk to you?’”

While Dr. Bedard emphasizes that determination of unacceptable risk level is an individual decision, for some patients needing TKA or THA, the pain level they are experiencing makes decision-making difficult. In this case, Dr. Bedard suggests the surgeon help guide them in a shared decision-making process.

#### MAYO CLINIC'S APPROACH TO HELPING INDIVIDUALS WITH HIGH BMI WHO NEED TKA OR THA

What Dr. Bedard recommends, in light of risks for the patient with high BMI who needs pain alleviation and functional improvement, is optimizing the patient's weight and health before surgery. This typically includes the following process with a surgeon, patient and other physicians who specialize in weight loss:

- Discussing the patient's arthroplasty risks and any patient concerns
- Setting reasonably attainable health improvement goals
- Presenting options for how to reach the goals and pros and cons of each potential tool

Dr. Bedard emphasizes compassion and a can-do attitude with patients in this situation, as many have been denied surgery elsewhere.

Mayo Clinic's BMI targets for TKA and THA are not different from those of other institutions. The distinction for Mayo Clinic lies in a multidisciplinary approach. Mayo

Clinic assists patients who have a high BMI reach the needed surgery — rather than turning them away — and refers patients for optimization. After patients in this situation meet goals and have surgery, Mayo Clinic offers teams to manage any potential complications.

The choice of how to pursue optimization rests with the patient in consultation with the surgeon. This may include working with the patient to eliminate smoking, or gain control of diabetes, swelling, ulcers or open wounds — all factors in lowering surgical risk.

Optimization also may include activity modification, injections, medications, and working with bariatric surgery and weight-loss teams to set goals — such as a BMI of 40 or recovering from malnutrition despite the patient's weight — or address any other symptoms. Some patients have bariatric surgery before TKA or THA. In other cases, the surgeon may arrange a weight-loss consult or work with a primary care provider or local weight-loss clinic.

Dr. Bedard is optimistic about potential weight-loss success during optimization. “I've seen many patients who have very high BMI lose weight successfully in the process,” says Dr. Bedard.

Dr. Bedard explains that despite optimization, these patients are still at high risk, and the care team must be pragmatic.

“We're unable to eliminate all possible risks,” he says. “We're about helping these patients and reducing their surgical risk to a more acceptable level.”

Referral considerations for physicians treating patients with high BMI who require arthroplasty Dr. Bedard indicates multiple options exist for physicians to help patients with a high BMI become ready for a TKA or THA. Community physicians should apply similar pre-surgical optimization strategies as those employed by Mayo Clinic. If a physician does not have access to resources to help optimize patients, one option to consider is referring the patient to Mayo Clinic.

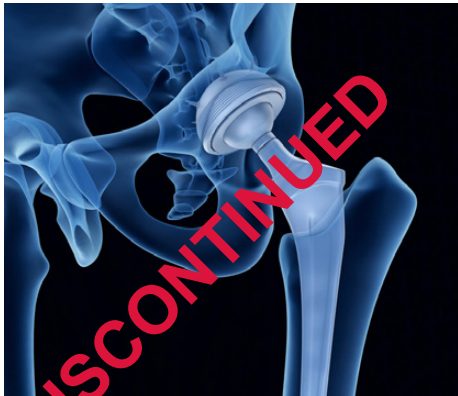

Figure 1. Total hip arthroplasty

## RPNI Lowers Post-Amputation Pain

Mayo Clinic is employing a new method of pain prevention as part of limb amputation, heading off post-amputation morbidity from the formation of neuromas (Figure 1, see page 7), which contribute to residual limb pain (RLP)

and phantom limb pain (PLP). Until recently, traditional interventions for post-amputation neuromas have been unsuccessful: Neuroma recurrence rates were high.

DISCONTINUED



The new method, regenerative peripheral nerve interface (RPNI), has been studied both preclinically and clinically. It prophylactically reduces potentially symptomatic neuromas through autologous free muscle grafts (Figure 2), often from the amputated limb, implanting the ends of transected nerves into the graft and supplying regenerating axons, reinnervating end organs and creating new neuromuscular functions.

“RPNI is active prevention of neuroma,” says Shelley S. Noland, M.D., a hand and peripheral nerve surgeon at Mayo Clinic’s campus in Arizona, and a major user of the RPNI technique. “Placing the nerve endings into muscle graft tissue gives the nerves somewhere to go and something to do.”

Although RPNI ideally is performed at the time of amputation, Dr. Noland explains that RPNI can be performed later, if a neuroma forms post-amputation. The surgeon resects the neuroma and performs the RPNI procedure, solving the anatomical issue. She notes if RPNI is performed after a neuroma forms, however, it can take significant time for the brain to stop registering pain, despite the procedure’s removing its source.

In the U.S., the most common type of amputation involves the lower extremity, says Dr. Noland. According to a study by Kathryn Ziegler-Graham, Ph.D., and colleagues published in a 2008 issue of *Archives of Physical Medicine and Rehabilitation*, as of 2005, 1 out of 190 U.S. individuals — 1.6 million people — had experienced limb amputation.

A projection for U.S. amputation volume for the year 2050 is 3.6 million individuals, barring a significant decrease in dysvascular disease — a condition with rising incidence currently — according to this study. Post-surgically, up to 80% of patients experience PLP, according to a 2021 publication in *Pain Reports* by Joachim Erlewein and colleagues. Of all amputees, 50% experience residual limb pain, according to Thomas Buchheit, M.D., and colleagues’ 2016 publication in *Pain Medicine*.

“Pain is a major issue post-amputation,” she says. “Neuromas are incredibly painful. They lead to chronic pain and a terrible cascade of issues.”

In a study published in a 2017 issue of *Prosthetics and Orthotics International* by Richa Sinha and colleagues, investigators found that pain from post-amputation neuroma is associated with decreased quality of life.

Dr. Noland says neuromas often become superficial, and patients can identify their precise locations and palpate them.

“Pain from a neuroma can be so intense that patients are less able to participate in daily life activities and may give up on prosthetic use,” says Dr. Noland.

“It’s hard to function if your prosthetic is pushing on a neuroma,” she explains. “You just can’t do it.”

Due to potential for significant morbidity post-amputation, Dr. Noland believes it’s important for surgeons who amputate limbs to mitigate pain during the amputation or by treating symptomatic neuromas post-amputation.

#### ACTIVE, EFFECTIVE PREVENTION VERSUS INCONSISTENT PASSIVE PREVENTION

The traditional method of deterring neuroma formation involved attempting to bury the nerve ends at the amputation site, effectively placing them away from the surface. However, Dr. Noland indicates high failure rates with these techniques, primarily because the buried nerves did not stay in place.

Physicians developed RPNI because former amputation techniques were inconsistently successful for pain prevention and did not offer the severed nerves a function, which all nerves instinctively seek.

“The old techniques didn’t give the nerves at the amputation site anywhere to go or anything to do,” Dr. Noland says. “A nerve will try to grow proximal to distal and when it has nowhere to go, it makes a tight hard ball of nerve scar. This was a passive approach to prevent neuroma, where RPNI is active prevention of neuroma.”

Additionally, RPNI is intended to be a long-term solution to post-amputation pain from neuroma formation. Dr. Noland reports she has not seen a neuroma develop after RPNI. She notes, however, that while there is some one-year follow-up for the procedure, clinical investigators are still working on



Shelley S. Noland, M.D.

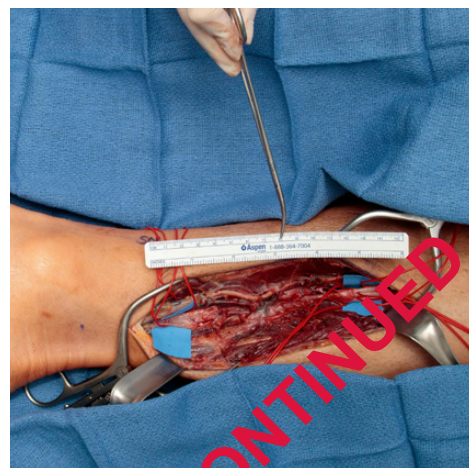


Figure 1. A surgical image of a neuroma in a patient’s lower extremity

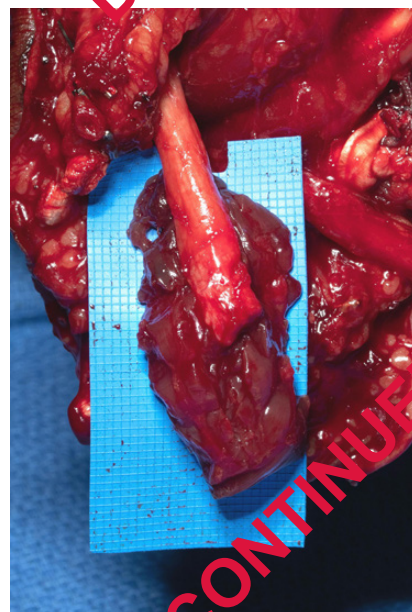


Figure 2. After neuroma excision, a neuroma excision, showing the placement in free muscle graft before securing with microsurgery.

determining long-term outcomes from RPNI as the procedure evolves.

#### SAFETY AND FEASIBILITY FOR MANY ORTHOPEDIC SURGEONS

According to a 2021 article published in *Annals of Vascular Surgery*, RPNI has proved to be safe. In addition, unlike other challenging-to-duplicate, extremely complex orthopedic surgical techniques, it is highly replicable by a wide spectrum of surgeons in the field.

#### AVAILABILITY OF RPNI

Dr. Noland says RPNI is not commonplace in the U.S. currently, and she believes the technique's potential is not yet widely known in the orthopedic community. To spread the word about RPNI, she is attempting to provide education for orthopedic surgeons, starting with home-base education about sarcoma cases at Mayo Clinic's campus in Arizona.

The technique requires both nerve and microsurgical expertise, a combination she says is far more common in academic medicine.

#### FOR MORE INFORMATION

Erlenwein J, et al. Clinical updates on phantom limb pain. *Pain Reports*. 2021;6:e288.

Buchheit T, et al. Pain phenotypes and associated clinical risk factors following traumatic amputation: results from veterans integrated pain evaluation research (VIPER). *Pain Medicine*. 2016;17:149.

Sinha R, et al. Factors affecting quality of life in lower limb amputees. *Prosthetics and Orthotics International*. 2017;35:90.

Kubiak CA. Decreasing postamputation pain with the regenerative peripheral nerve interface (RPNI). *Annals of Vascular Surgery*. 2021;79;421.

Ziegler-Graham K, et al. Estimating the prevalence of limb loss in the United States: 2005 to 2050. *Archives of Physical Medicine and Rehabilitation*. 2008;89:422.

#### Contact Us

Mayo Clinic welcomes inquiries and referrals, and a request to a specific physician is not required to refer a patient.

**Phoenix/Scottsdale, Arizona**  
866-629-6362

**Jacksonville, Florida**  
800-634-1417

**Rochester, Minnesota**  
800-533-1564

#### Resources

**MayoClinic.org/medicalprofessionals**

Clinical trials, CME, Grand Rounds, scientific videos and online referrals

#### Orthopedic Surgery Update

*Mayo Clinic Orthopedic Surgery Update* is written for physicians and should be relied upon for medical education purposes only. It does not provide a complete overview of the topics covered and should not replace the independent judgment of a physician about the appropriateness or risks of a procedure for a given patient.

**Medical Editor**  
John W. Sperling, M.D.

**Cover image:**  
Skeletal muscle cells, fluorescence light micrograph

Credit: Daniel Schroen, Cell Applications Inc. / Science Photo Library

*Orthopedic Surgery Update* (MC6247-0222) is published by ©2022 Mayo Foundation for Medical Education and Research. All rights reserved. Mayo, MAYO CLINIC and the triple-shield Mayo logo are trademarks and service marks of Mayo Clinic, 200 First St. SW, Rochester, MN 55905. Periodicals postage paid at Rochester, Minn., and at additional mailing offices.

## Education Opportunities

For more information or to register for courses, visit <https://ce.mayo.edu/group/orthopedic-surgery>, call 800-323-2688 or email [cme@mayo.edu](mailto:cme@mayo.edu).

#### 31ST ANNUAL MAYO CLINIC SYMPOSIUM ON SPORTS MEDICINE

Nov. 4-5, 2022

Rochester, Minn., and Livestream

This course features evidence-based and cutting-edge diagnostic and treatment strategies for sports-related and musculoskeletal conditions. The program is multidisciplinary, with expert lecturers representing a spectrum of sports medicine fields.

#### COMPREHENSIVE SHOULDER AND ELBOW COURSE: CURRENT CONCEPTS AND CONTROVERSIES 2023

Feb. 2-4, 2023

Scottsdale, Ariz.

This course presents treatment options for shoulder and elbow arthroscopy, arthroplasty, fracture and reconstruction. Internationally recognized faculty provide insights and tips for treating shoulder and elbow disorders.